

# Sudden infant death syndrome as a result of thymic-lymphatic dysgenesis

Saule Amangeldievna Mussabekova<sup>1</sup>, Elena Igorevna Burkova<sup>1</sup>, Kristina Ergardovna Dobler<sup>2</sup>, Balzhan Smailovna Muldasheva<sup>2</sup>, Zhan Zhumagulovich Atmtaev<sup>2</sup>

<sup>1</sup> Department of Morphology, Medical University of Karaganda, Karaganda, Kazakhstan

<sup>2</sup> Institute of Forensic Examinations in Karaganda, Center for Forensic Examination of the Ministry of Justice of the Republic of Kazakhstan, Karaganda, Kazakhstan

Received: 2023-12-20.

Accepted: 2023-02-10.



This work is licensed under a  
Creative Commons Attribution 4.0  
International License

J Clin Med Kaz 2024; 21(1):97-100

Corresponding author:

Elena Igorevna Burkova

e-mail: [Alenushka\\_fiery@mail.ru](mailto:Alenushka_fiery@mail.ru)

ORCID: 0000-0002-0062-4337

## Abstract

Sudden infant death syndrome is one of the leading causes of post-neonatal mortality. The thymic-lymphatic condition in children is a clinically rare manifestation and difficult to diagnose condition, assessed as a background, realized in a number of cases of sudden death syndrome. However, the clinical and histopathological manifestations of thymic-lymphatic status may not be clearly expressed. We present an unusual case of sudden infant death syndrome as a result of thymic-lymphatic dysgenesis complicated by acute adrenal insufficiency.

**Keywords:** forensic medical examination, thymic-lymphatic dysgenesis, thymus hyperplasia, thymic-lymphatic status, sudden infant death syndrome.

## Introduction

In a number of countries, sudden infant death syndrome (SIDS) occupies a leading position in the structure of child mortality. The prevalence of SIDS in the world is 0.2-1.5 cases per 1000 children. Sudden death in children (without sudden cardiac death syndrome) accounts for 5-10% of all child deaths, which is about 1.3-4.0 per 100,000 population [1]. Thus, the average mortality rate from SIDS per 1000 births is: in Japan - 0.25, the Netherlands - 0.3, Russia - 0.4, Great Britain - 2.3, Germany - 1.6, Austria - 1.0, Italy - 0.5, the USA - 2.8, in Russia - 0.43 per 1000 children [2]. In Kazakhstan, the infant mortality rate in 2021 was 8.41, but the data on deaths of children from SIDS were not allocated to a separate category [3]. Thymic-lymphatic status (Latin: Status Thymico-Lymphancus) is a condition of the body characterized by pathological hyperplasia of the thymus gland or in combination with generalized hyperplasia of the entire lymphoid tissue, including lymph nodes, palatine tonsils, spleen, as well as atrophic changes in the adrenal glands, causing sudden death from influences whose strength is inadequate to a fatal outcome [4]. Thymic-lymphatic status was the background of the underlying disease, contributing to the development of sudden death syndrome [5,6]. Timely verification of this condition is an urgent issue of medical practice, and therefore the presented case of sudden death of a child as a result of thymico-lymphatic dysgenesis is of particular interest to the medical community.

## Case presentation

The sudden death of a two-year-old child was recorded in a private kindergarten. Upon examination of the incident, no signs of violent death were found. During the examination of the child's corpse by a forensic medical expert, only small-point hemorrhages of dark red color were found on the mucous membrane of the upper eyelid of the right eye, bodily injuries (bruises, abrasions, wounds) were not found.

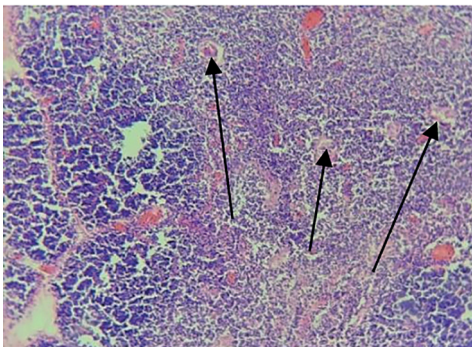
An external examination of the corpse during the forensic medical examination confirmed the complete absence of traces of any injections, rashes, swellings, scabs, ulceration, congenital or acquired anatomical defects or individual characteristics on the child's body. All bones of the child's skeleton are intact, without pathological mobility and deformation.

An internal forensic examination of the corpse confirmed the absence of damage to the bones of the cranial vault and congenital pathologies: all brain structures are pathology-free and age-appropriate. Autopsy of internal organs revealed thymomegaly (dimensions 11.8 x 6.9 x 5.6 cm, weight 41 grams) and splenomegaly (dimensions 12.0 x 7.2x3.8 cm, weight 54.5grams), other organs without features, macroscopically no pathology was found.

Materials from the brain, heart, liver, kidneys, lungs, spleen, adrenal glands, thymus and pancreas were seized for laboratory studies. The fixation of the material was carried out in a 100% formalin solution, alcohol wiring

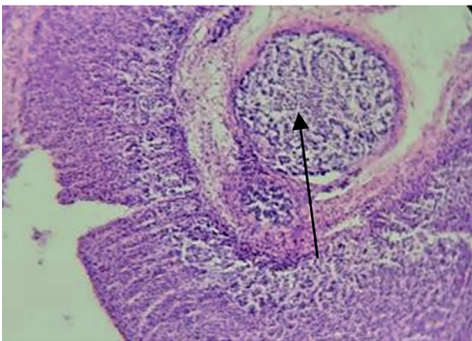
was used, followed by the manufacture of paraffin blocks with staining of the obtained micropreparations with hematoxylin-eosin and the conclusion of micropreparations in a Bio Mount HM medium. Microscopic studies were performed using a Leica DM500 microscope with a magnification of 100x.

Microscopy of the thymus shows large lobules, the stroma between the lobules is wide and loose, there is no separation of layers, the ratio of layers is 3:1 with a sharp predominance of the cortical layer over the cerebral one, the Hassall's bodies are small, small, with pronounced dystrophic changes, arranged randomly with varying degrees of calcification (Figure 1). These signs made it possible to diagnose hyperplasia of the cortical layer of the thymus with pronounced dystrophic changes in the Hassall's bodies.

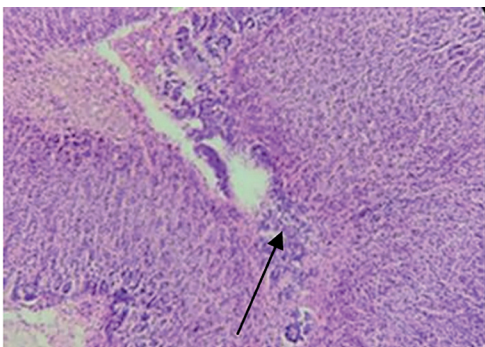


**Figure 1** - Thymus: pronounced dystrophic changes in Hassall's bodies

A forensic histological examination of the adrenal glands revealed: the boundary between the cortical and cerebral substance is weakly expressed, the cerebral layer is sharply reduced, additional lobules are noted in the cortical layer (Figure 2), almost all cells are filled with vacuoles, the vessels are thin, full-blooded. The obtained microscopic data allowed us to verify: nodular hyperplasia of the adrenal cortex (the presence of additional adrenal lobules) and hypoplasia of the adrenal medulla (Figure 3), as well as large-focal adrenal delipidization and plethora of adrenal vessels.



**Figure 2** - Adrenal gland: accessory lobule



**Figure 3** - Adrenal gland: adrenal medulla hypoplasia

The analysis of the microscopic picture of the spleen revealed a sharp hyperplasia of the red pulp, a mass of small and large lymphoid follicles without formed enzymatic centers with a large number of lymphoid cells and thin vessels, weak blood filling, which indicates hyperplasia of the red pulp of the spleen and its weak blood filling, reduction of lymphoid follicles of the spleen.

Microscopy of the brain revealed a significant expansion of the perivascular and pericellular spaces due to edema. The neurocytes are swollen, with clear and pale nuclei. The soft meninges are loose, with pronounced edema. The vessels are thin, full-blooded. The revealed morphological changes are signs of pronounced edema and fullness of the brain and soft meninges, as well as focal vasculitis in the soft meninges.

In the heart: cardiomyocytes of normal size, granular, with clear nuclei, there are areas of cardiomyocyte discomplexation, edematous stroma, thin intramural vessels, weak blood filling and sometimes spasmodic. The revealed structural changes indicate granular dystrophy and focal discomplexation of cardiomyocytes with stroma edema, as well as anemia and focal spasm of intramural vessels.

In the lungs: the pleura is loose, full-blooded, the interalveolar septa are thin and full-blooded, in places with diffuse lymphoid infiltration, the septa in some areas are torn apart, forming small voids. The lumen of the alveoli in many areas is filled with edematous fluid. The bronchi are scalloped in shape, the epithelium is desquamated into the lumen. The vessels are thin, full-blooded, and lymphoid infiltration is noted around some vessels. The detected pathomorphological changes indicate focal interstitial pneumonia, acute focal emphysema and focal protein edema of the lungs, focal bronchospasm and pulmonary vascular fullness.

In the liver: the capsule is thin, the beam-radial structure of the lobules is preserved. Hepatocytes with granular cytoplasm, nuclei are clearly visible in all cells. The inter-girder spaces are moderately expanded, due to edema. The portal tracts are thin. The vessels are thin, full-blooded. All this confirms the presence of granular liver dystrophy with fullness of its vessels.

In the kidneys: the capsule is loose and full-blooded, the glomeruli are rounded, full-blooded. The epithelium of the tubules is high and cloudy, with vacuolated cytoplasm, the nuclei are clearly visible. The stroma is loose, the vessels are thin and full-blooded. Vacuole dystrophy of the kidneys and fullness of the renal vessels have been identified. Morphological changes in the studied organs are characteristic of "acute death".

Based on the external and internal examination of the child's corpse and the morphological data obtained, a forensic medical diagnosis was made:

1. Thymic-lymphatic dysgenesis R94.7 (macroscopically: thymomegaly, splenomegaly, adrenal hypoplasia. microscopically: nodular hyperplasia of the adrenal cortex (the presence of additional adrenal lobules), hypoplasia of the adrenal medulla, large-focal delipidization of the adrenal glands; hyperplasia of the cortical layer of the thymus, pronounced dystrophic changes in the Hassall bodies; hyperplasia of the red pulp of the spleen).

2. Acute adrenal insufficiency.

3. Acute focal interstitial pneumonia.

During the examination of the child's corpse, morphological signs of acute focal interstitial pneumonia were found, which are causally related to the onset of death.

## Discussion

All cases of sudden death of children without signs of violent death are usually a matter of concern for forensic medical experts [7-9]. According to R. W. Byard, all autopsies of SVSD should undergo a structured examination aimed at identifying the main causes of sudden death [10]. The mechanisms leading to sudden and unexpected death seem complex and multifactorial and require the coordination of several overlapping factors in order for death to occur [11, 12]. In this case, a thorough full autopsy was performed in accordance with the Rules of organization and production of forensic medical examination in the Republic of Kazakhstan, due to the lack of other macroscopic, histological and toxicological data, the authors assumed that the cause of death of the child was thymic-lymphatic dysgenesis complicated by acute adrenal insufficiency. Autopsy showed that the thymus was enlarged, of a soft elastic consistency, pinkish-gray in color with a slightly pronounced lobulation, weighing 41.0 grams and measuring 11.8 x 6.9 x 5.6 cm. Usually, the mass of the thymus at birth is 12-15 grams, during puberty - 30-40 grams, at the age of 60 – 10-15 grams [13]. Histologically, no changes, signs of thymoma or other diseases of the thymus were found in the thymus. Consequently, an increase in the mass and size of the histologically preserved thymus determines the true hyperplasia of the thymus [4, 8, 14].

Such data prompted the authors to discuss the theory of the so-called "thymic death", expressed at the end of the XIX century by a number of authors who testified that hyperplastic thymus can lead to tracheal obstruction and sudden death of infants and described "thymus death" as a systemic disease accompanied by an increase in all lymphoid tissues, which can lead to sudden death from heart disease-vascular collapse [15]. The theory of "thymicus-lymphaticus status", confirmed by more than 800 publications, has dominated for 30 years in cases of sudden infant death [12]. Later, a theory was developed (1942, Pende) of "constitutional hyperthymic syndrome" or "Pende syndrome", a condition characterized by an increase in the volume and activity of the thymus from birth, macrosomia and poor development of the genitals during puberty [16]. However, some scientists have insisted that since the thymus is affected within a few days after the disease, it reaches large sizes only if the patient dies suddenly [1, 17].

In 1931, The Lancet magazine published an editorial entitled "The End of the status of Lymphaticus", supporting Greenwood's theory, as a result of which the status of "thymic-lymphatic" was included in the list of "historical medical errors" in 2000 [15]. According to the opinion of N. Rackham, the corpses studied earlier to determine the "normal" size of the thymus belonged to poor people who usually died from severe chronic diseases (e.g. tuberculosis, infectious diseases) or malnutrition that cause stress-related thymus involution: therefore, they simply underestimated the size and weight of the "normal" thymus gland. Consequently, in infants and young people who died suddenly, it was mistakenly believed that they had an enlarged thymus gland [18]. However, later the theory of "thymic death" was revived due to a number of studies: a link was found between mortality associated with cardiovascular diseases and higher thymus weight [19, 20] and patients with atrioventricular node tumors, Langerhans islet hyperplasia, multicystic ovaries, adrenal heterotopia, right kidney clear cell adenomatosis and hyperplasia were described thymus, which indicates a unique genetic defect [21]. In 2017, Zou et al. autopsies of adult corpses from 1984 to 2014 were analyzed and found that thymus hyperplasia significantly increases the

risk of sudden unexpected death in young people, both men and women, mainly from cardiovascular diseases [22].

Researchers have proved that the thymus is a link between the immune and endocrine systems, however, its full physiological role is still not fully understood [23]. An analysis of the literature has shown that massive thymus hyperplasia, a rare variant of true thymus hyperplasia, is extremely rare during the first two decades of life and can clinically cause compression of the mediastinum or acute and recurrent pulmonary infection [24]. Thymus hyperplasia in adults has been widely studied for a fairly long period, namely, the diagnosis of thymus hyperplasia is based on microscopic signs [19].

According to previous studies, in the period from 1975 to 2020, only 10 cases of this pathology were registered in children aged < 1 year of life, while the prevalence of males among them (70%) was noted, nine out of ten children had initial symptoms or signs associated with the respiratory system, and Respiratory distress was observed in six patients, and surgical thymectomy was successfully performed in all patients without any postoperative complications [9, 24]. However, when detecting thymus hyperplasia, it is necessary to remember about the possibility of a secondary process against the background of various diseases, as well as neoplasms [10, 14]. According to some studies, persons with thymic-lymphatic dysgenesis are characterized by biological instability, as a result of which sudden death may occur from the effects of some, even minor, factors [25]. The presented case allowed the authors to prepare the basis for increased attention to the thymus in subsequent cases of sudden death. Whether there is a link between sudden death and thymus hypertrophy, and if so, how, is a matter for further investigation.

**Author Contributions:** Conceptualization, S. M.; methodology, K. D.; validation, B. M.; formal analysis, B. M.; investigation, Zh. A.; resources, K. D.; data curation, E. B.; writing – original draft preparation, E. B.; writing – review and editing, S. M.; visualization, K. D.; supervision, S. M.; project administration, S. M.; funding acquisition – not applicable. All authors have read and agreed to the published version of the manuscript.

**Disclosures:** There is no conflict of interest for all authors.

**Acknowledgements:** None.

**Funding:** None.



## References

1. Vincent A, Chu NT, Shah A, Avanthika C, Jhaveri S, Singh K, Limaye OM, Boddu H. Sudden Infant Death Syndrome: Risk Factors and Newer Risk Reduction Strategies. *Cureus*. 2023; 15(6): e40572. <https://doi.org/10.7759/cureus.40572>.
2. Gras-Le Guen C, Franco P, Plancoulaine S. Editorial: Sudden infant death syndrome: Moving forward. *Front. Pediatr.* 2022; 10: 972430. <https://doi.org/10.3389/fped.2022.972430>.
3. Mussabekova S, Stoyan A. The case of determining the species, gender, age and race of the skull with congenital multiple developmental anomalies. *J CLIN MED KAZ.* 2022; 19(1): 80-4. <https://doi.org/10.23950/jcmk/11682>.
4. Khan MA, Anjum F. Thymic Hyperplasia. In: StatPearls [Internet]. Treasure Island (FL): StatPearls Publishing. 2023.
5. Grassi S, Pinchi V, Campuzano O, Oliva A, Brugada R. Editorial: Genetics of sudden unexplained death in children and young adults: state of the art, testing and implications for translational research, public health and forensic pathology. *Front. Med.* 2023; 10: 1309179. <https://doi.org/10.3389/fmed.2023.1309179>.
6. Karataeva LA. Sindrom vnezapnoj smerti i ego sovremennye aspekty [in Russian]. *Medicus*. 2020; 3(33): 68-70.
7. Zakharov MV, Fedulova MV, Pigolkina Yul. Sudden death in school-aged children at physical exercise: forensic diagnosis. *Sudebno-Meditsinskaya Ekspertisa*. 2021; 64(4): 64-67. <https://doi.org/10.17116/sudmed20216404164>.
8. Claes L, Dendooven A, van Heerden J. Challenges in diagnosing ectopic thymus tissue in children. *BMJ Case Rep.* 2019; 12(9): e228807. <https://doi.org/10.1136/bcr-2018-228807>.
9. Varga I, Bódi I, Mešťanová V, Kováč M, Klein M. Association between histological alterations in the thymus and sudden infant death syndrome. *J Forensic Leg Med.* 2018; 55: 8-13. <https://doi.org/10.1016/j.jflm.2018.02.007>.
10. Byard RW. Thymic changes and sudden infant death syndrome (SIDS). *J Forensic Leg Med.* 2019; 61: 141. <https://doi.org/10.1016/j.jflm.2018.09.004>.
11. Avanesjan HA, Berljaj MV, Kopylov AV, Korobkeev AA, Karpov SM. Sudebno-medicinskaja diagnostika morfologicheskikh izmenenij pri sindrome vnezapnoj detskoj smerti [in Russian]. *Medicinskij vestnik Severnogo Kavkaza*. 2018; 13(4): 667-671.
12. Qu D, Preuss V, Hagemie L, Radomsky L, Beushausen K, Keil J, et al. Age-related cytokine imbalance in the thymus in sudden infant death syndrome (SIDS). *Pediatr Res.* 2023. <https://doi.org/10.1038/s41390-023-02809-6>.
13. Tolstova EM, Zajceva OV. Fiziologija i patologija timusa v detskom vozraste [in Russian]. *Pediatrics. Zhurnal im. G. N. Speranskogo*. 2018; 97 (6): 166-172.
14. Guleria P, Jain D. Thymic lesions of the paediatric age group: a comprehensive review of non-neoplastic and neoplastic etiologies. *Mediastinum*. 2019; 3: 24. <https://doi.org/10.21037/med.2019.05.04>.
15. Borisenko NS, Popugajlo MV. Timiko-limfaticeskij status kak istoricheskij fenomen v medicine [in Russian]. *Vestnik UGMU*. 2023; 2: 62-72.
16. Weis CA, Märkl B, Schuster T, Vollert K, Ströbel P, Marx A. True thymic hyperplasia: Differential diagnosis of thymic mass lesions in neonates and children. *Pathologe*. 2017; 38(4): 286-293. <https://doi.org/10.1007/s00292-017-0283-z>.
17. Mlika M, Yaiche R, Fourti A, Braham E, Houcin Y, Marghli A, Mezni F. Thymic hyperplasia: A study of 46 cases. *Ann Pathol.* 2021; 41(6): 544-548. <https://doi.org/10.1016/j.annpat.2021.01.003>.
18. Benevento M, Nicoli S, Ferorelli D. Sudden cardiac death and thymic hyperplasia in adults: myth or reality? A case report. *Egypt J Forensic Sci.* 2023; 13: 37. <https://doi.org/10.1186/s41935-023-00357-y>.
19. Tsuda T, Fitzgerald KK, Temple J. Sudden cardiac death in children and young adults without structural heart disease: a comprehensive review. *Rev. Cardiovasc. Med.* 2020; 21(2): 205-216. <https://doi.org/10.31083/j.rcm.2020.02.55>.
20. Serfilippi LM, Quance JL. Pathology in Practice. *J Am Vet Med Assoc.* 2018; 253(2): 173-176. <https://doi.org/10.2460/javma.253.2.173>.
21. Chen C, Zhang C, Deng Y, Du S, Wang H, Li D. Thymic hypoplasia induced by copy number variations contributed to explaining sudden infant death based on forensic autopsies. *Forensic Sci Int.* 2022; 336: 111323. <https://doi.org/10.1016/j.forsciint.2022.111323>.
22. Zou L, Zhang Y, Zhu R. Thymic Hypertrophy and Sudden Unexpected Death in Adults – A Retrospective Study Of 56 Autopsy Cases. *International Journal of Human Anatomy*. 2017; 1(1): 9-20. <https://doi.org/10.14302/issn.2577-2279.ijha-17-1538>.
23. Bhalla P, Su DM, van Oers NSC. Thymus Functionality Needs More Than a Few TECs. *Front Immunol.* 2022; 13: 864777. <https://doi.org/10.3389/fimmu.2022.864777>.
24. Yang M, Zeng L, Ji Y, Xiang B, Xu ZC. Massive true thymic hyperplasia in a 3-month-old infant: case report and literature review. *Turk J Pediatr.* 2021; 63(4): 721-726. <https://doi.org/10.24953/turkjpmed.2021.04.022>.
25. Jiao J, Yu J, Chen C, Chen T, Zheng T, He L, Zeng Q. Thoracoscopic approach for massive thymic hyperplasia in an infant: Case report and literature review. *Front Pediatr.* 2023; 11: 1144384. <https://doi.org/10.3389/fped.2023.1144384>.